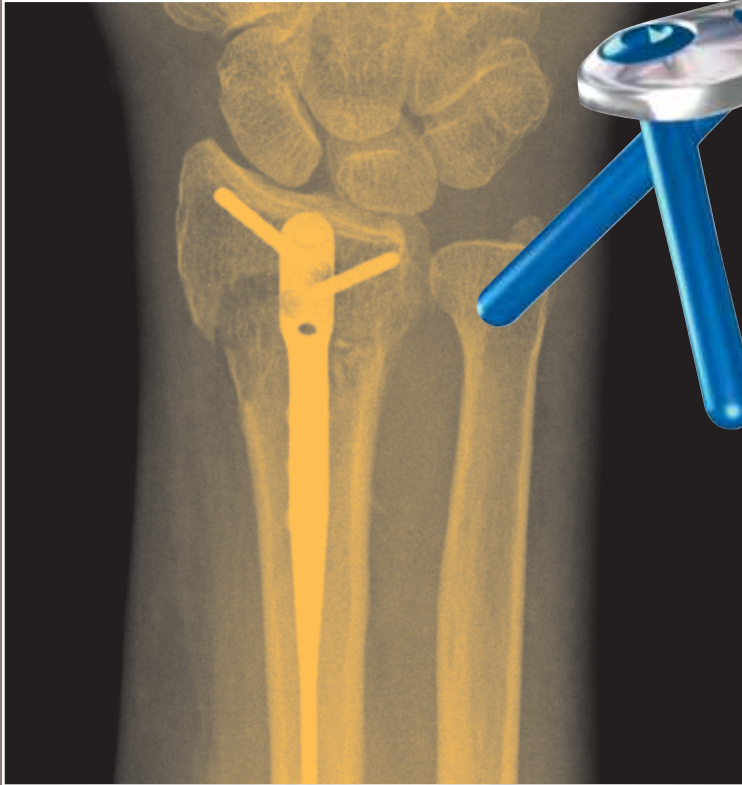
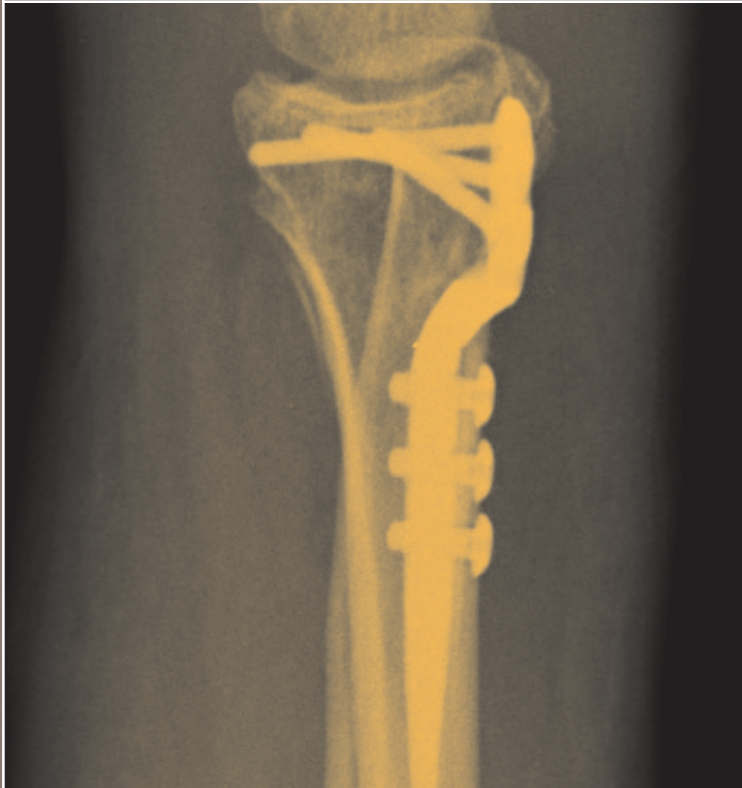
hand innovations
minimally invasive dorsal endoplate



surgical technique
for the dnp plate.



introducing the minimally invasive dorsal nail plate



minimizes extensor
tendon irritation

...

minimally invasive distal
radius fracture repair

...

fixed angle support

...

narrow profile

...

intramedullary locked
fixation

...

subchondral support
pegs

for more information contact:



8905 sw 87th avenue, suite 220

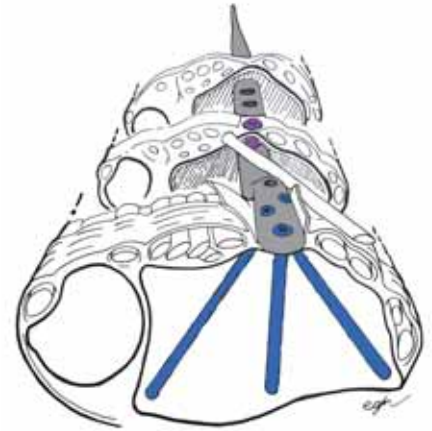
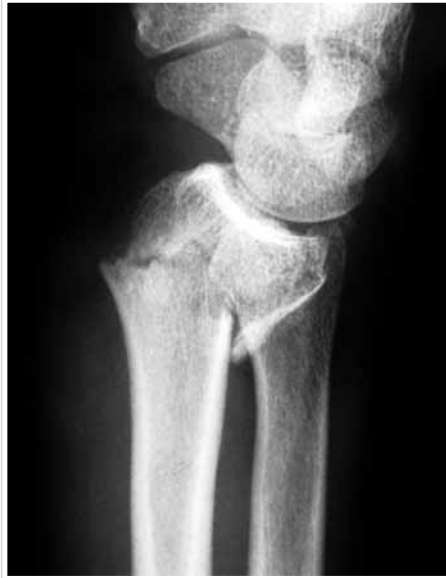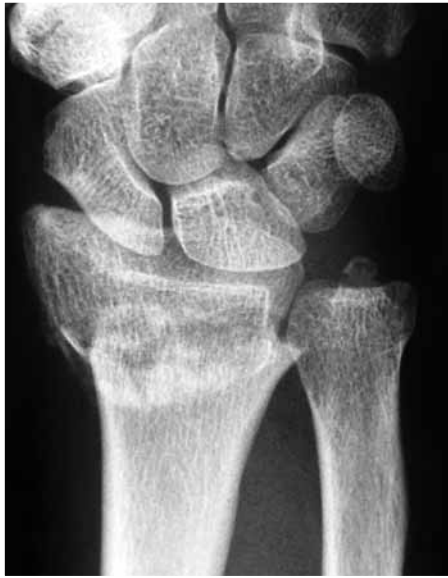miami, florida 33176

telephone: 305.412.8010

fax: 305.412.8060

toll free no.: 800.800.8188

www.handinnovations.com



introduction:

The Hand Innovations Dorsal Nail-Plate is a fixed angle implant designed for minimally invasive treatment of distal radius fractures.

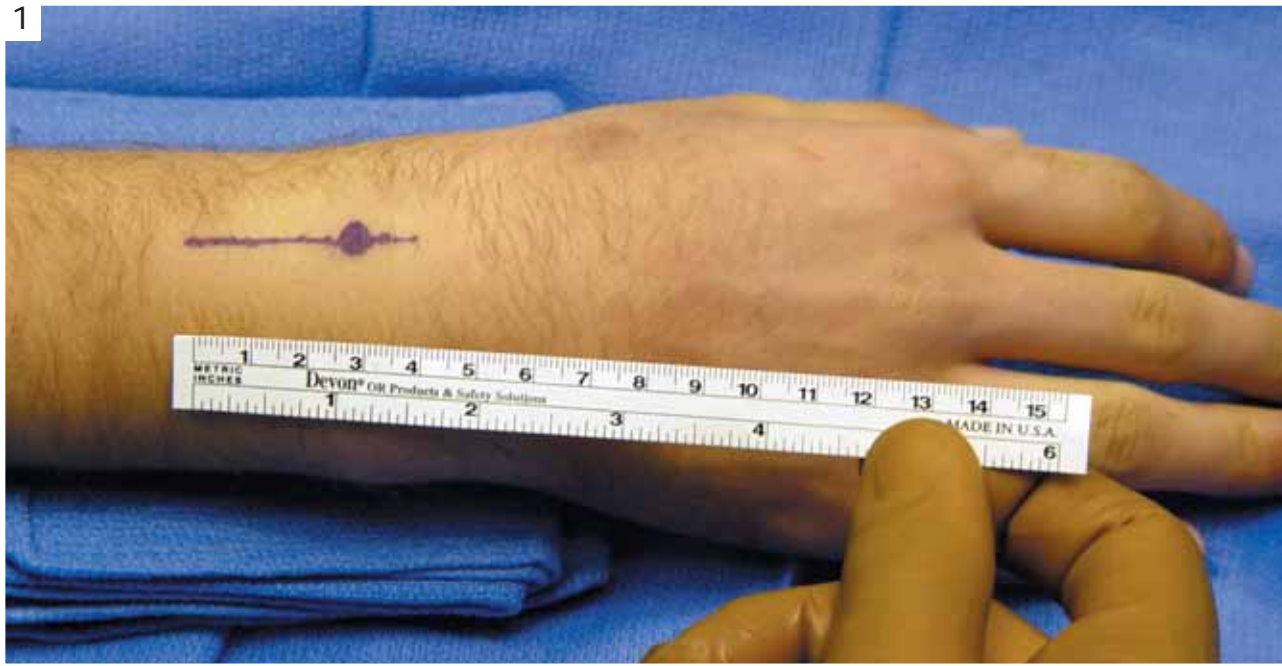
indications:

This device is intended for use in cases where minimal surgical exposure is desirable, articular involvement is not severe and reduction can be achieved by closed means. Fractures in the elderly patient where regional anesthesia is preferred and fractures in the polytraumatized patient where surgical time must be kept at a minimum are ideal indications.

surgical approach:

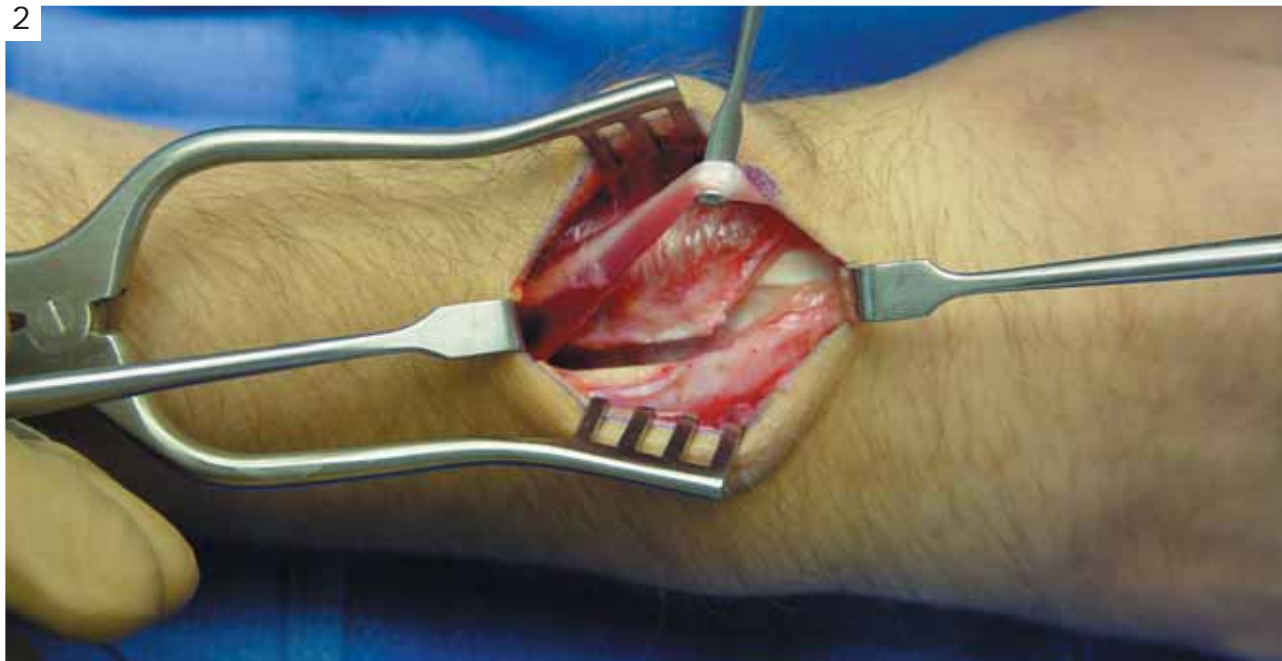The dorsal nail-plate is applied on the dorsal aspect of the radius. It avoids extensor tendon dysfunction by having a minimal extraosseal bulk; the head of the implant fits on the floor of the 3rd compartment and between the extensor tendons. Its application requires mobilization of the EPL tendon and subperiosteal exposure of Lister's tubercle.

1

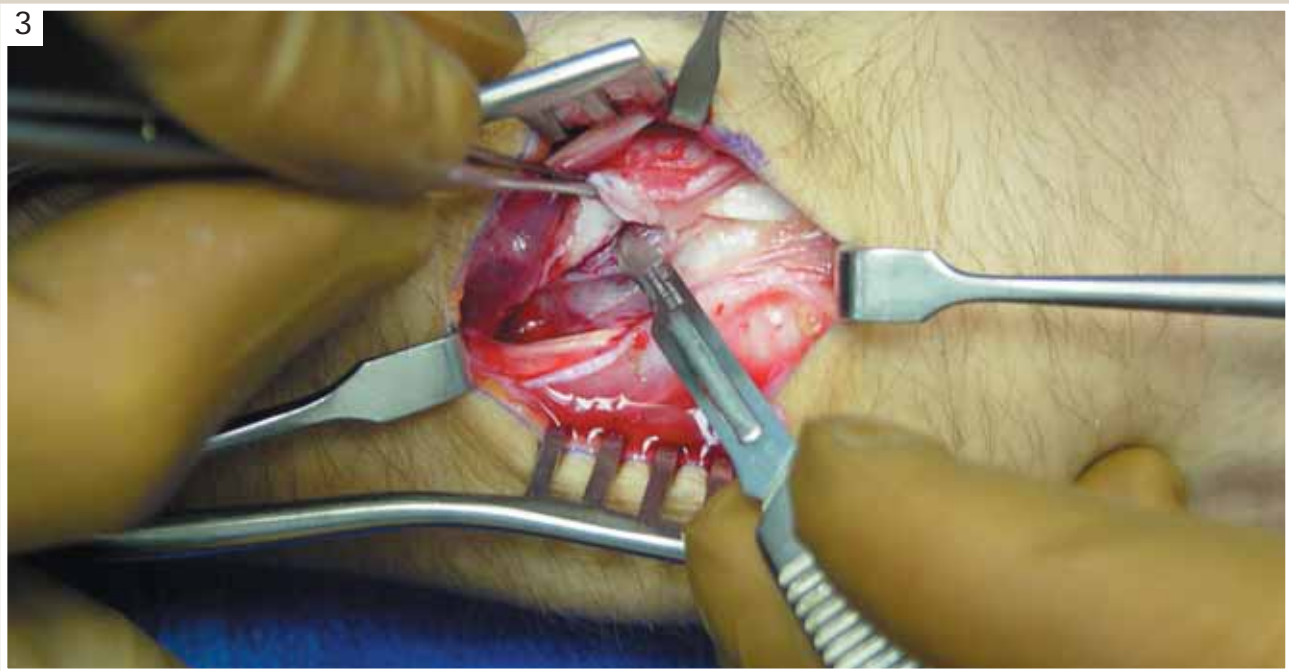


Make a 3-4 cm longitudinal incision overlying the distal radius and in line with Lister's tubercle.

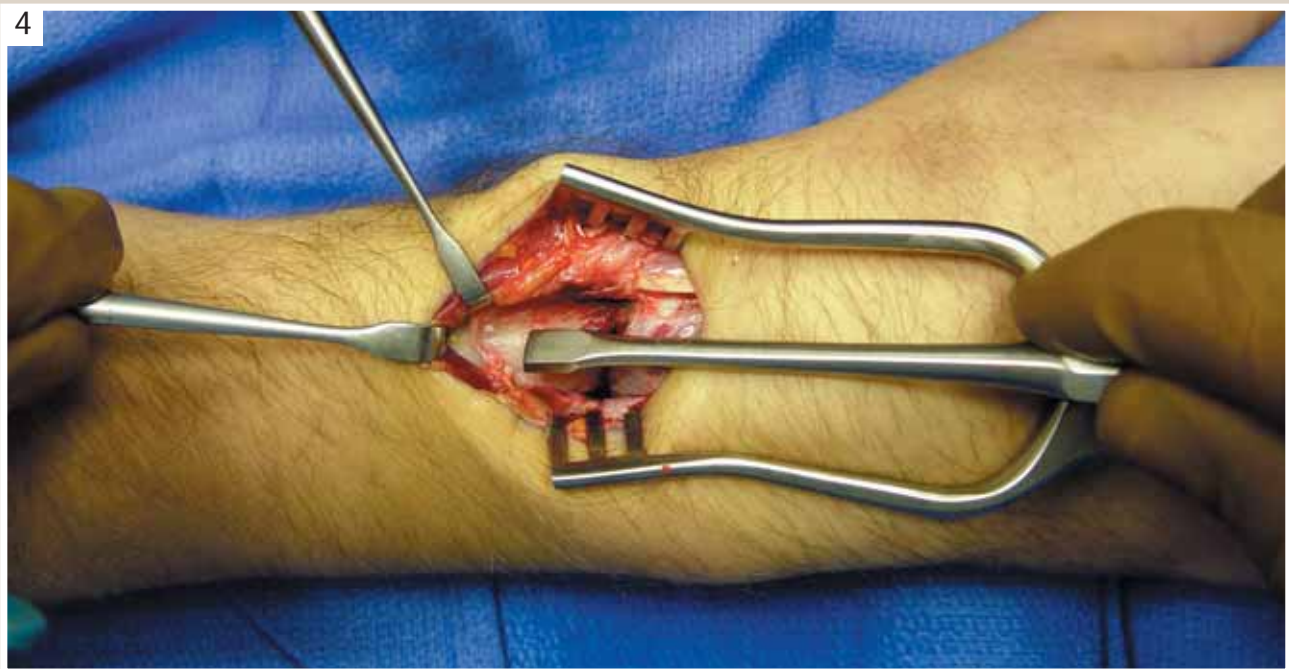
2



Release the EPL tendon sheath (3rd compartment) several cm proximal and distal to Lister's tubercle. Protect branches of the radial sensory nerve especially during the distal part of this dissection. Retract the EPL tendon towards the radial side.

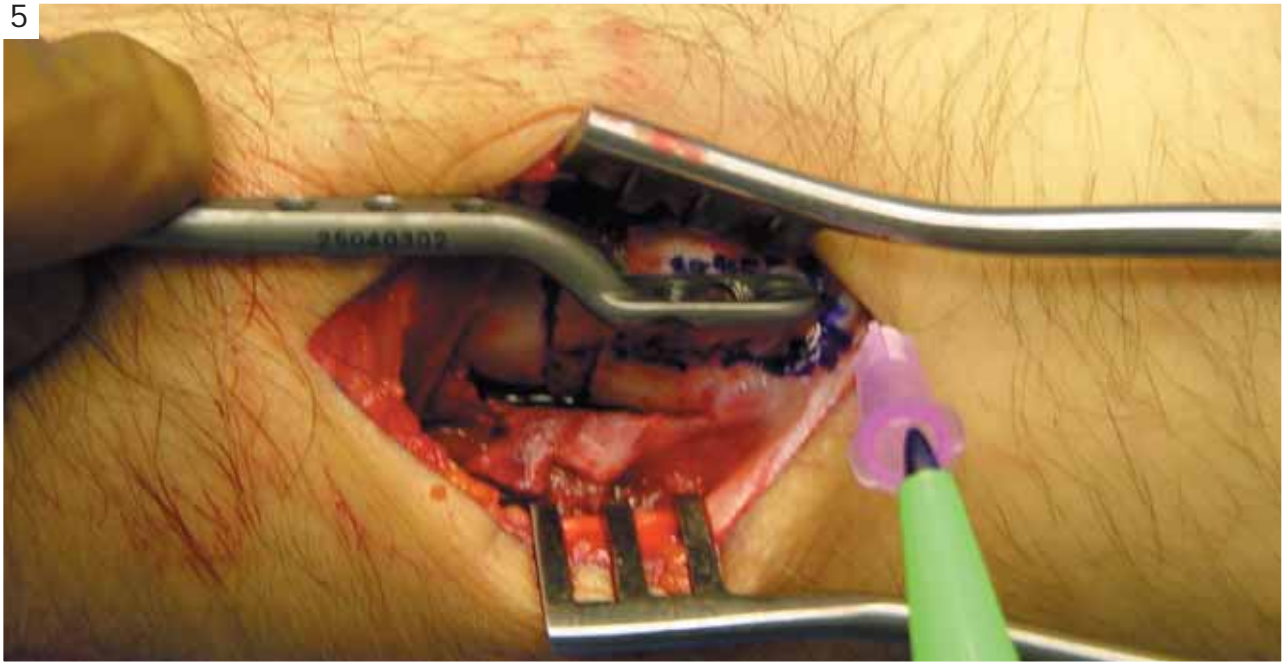


Expose Lister's tubercle subperiosteal ly.



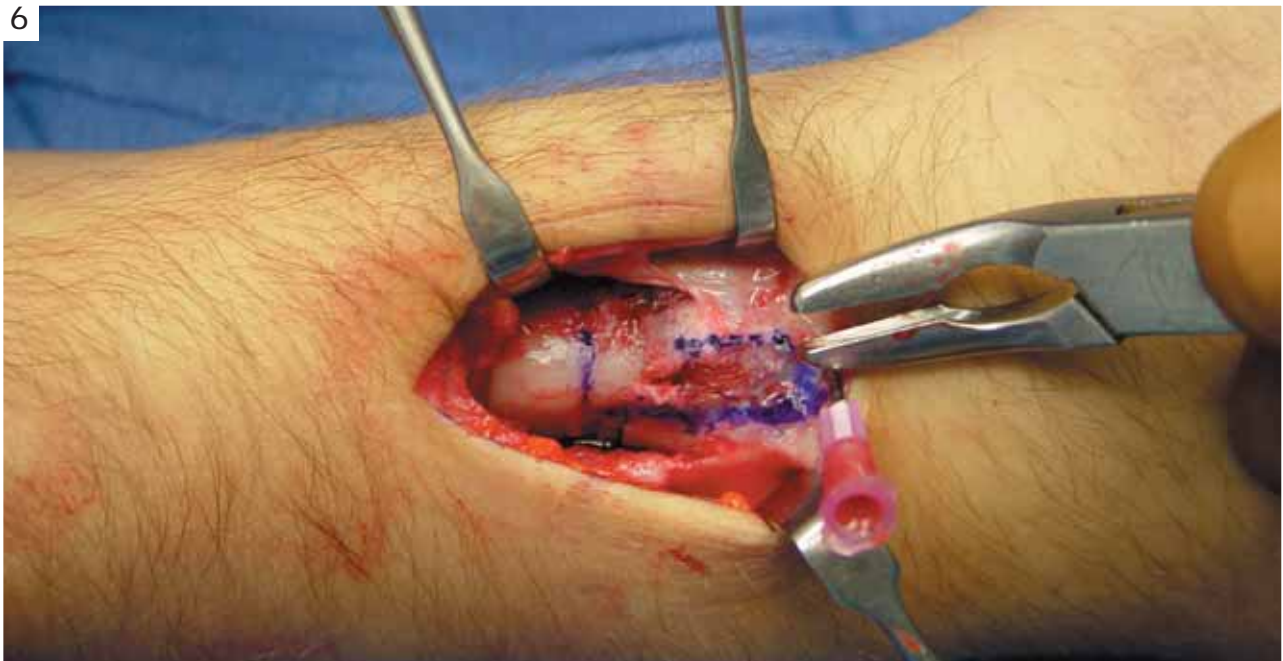
Carry the dissection proximal ly to expose the fracture site and the dorsal radius.

5



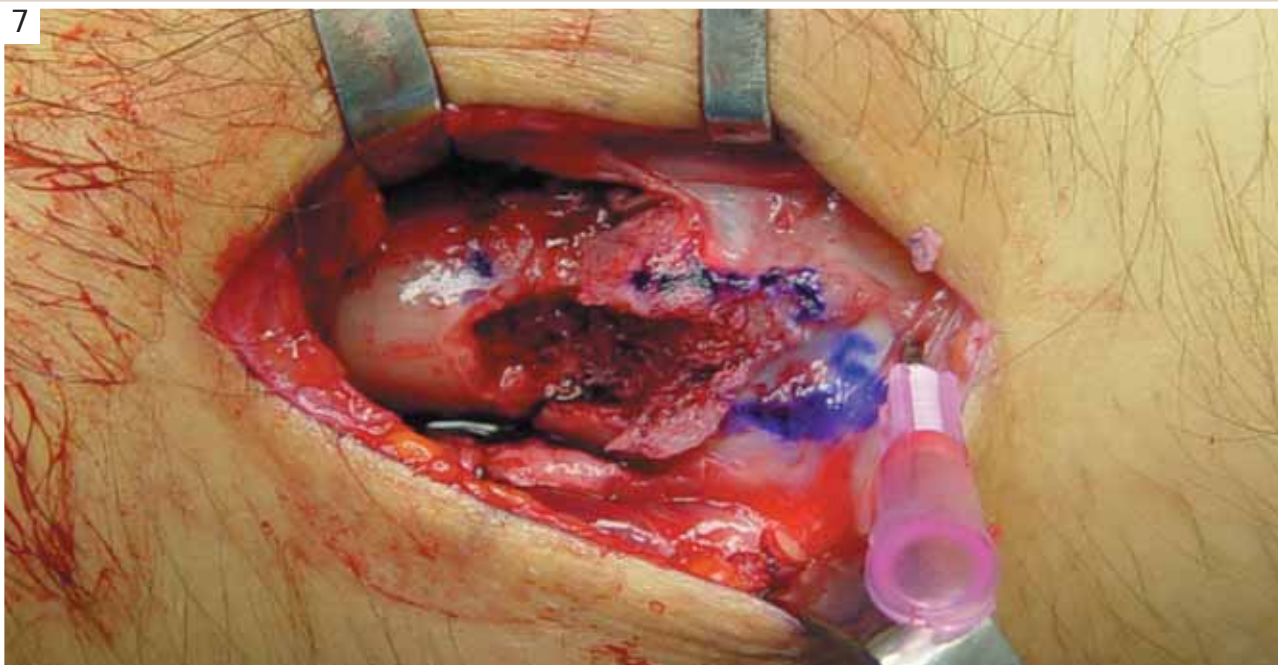
Insert an 18 gage needle to locate the joint line; the distal edge of the implant will rest 4 mm. proximal to it. Using a marking pen, draw the silhouette of the head and neck of the implant.

6



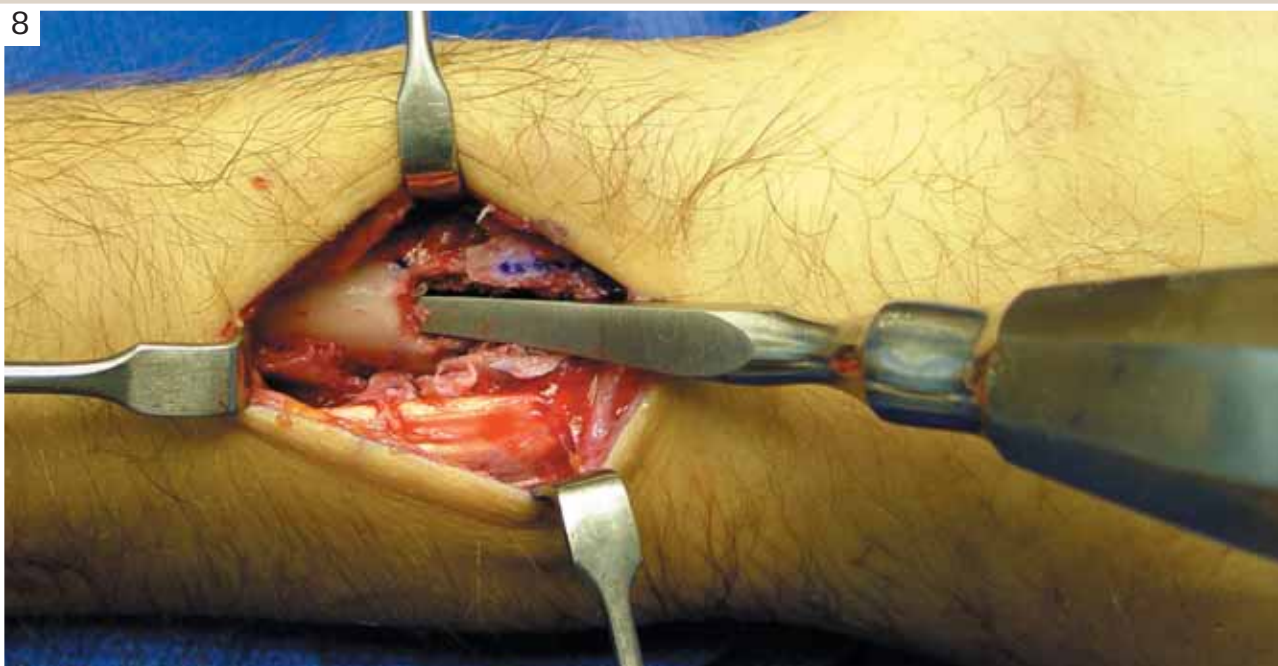
With a rongeur, remove Lister's tubercle.

7



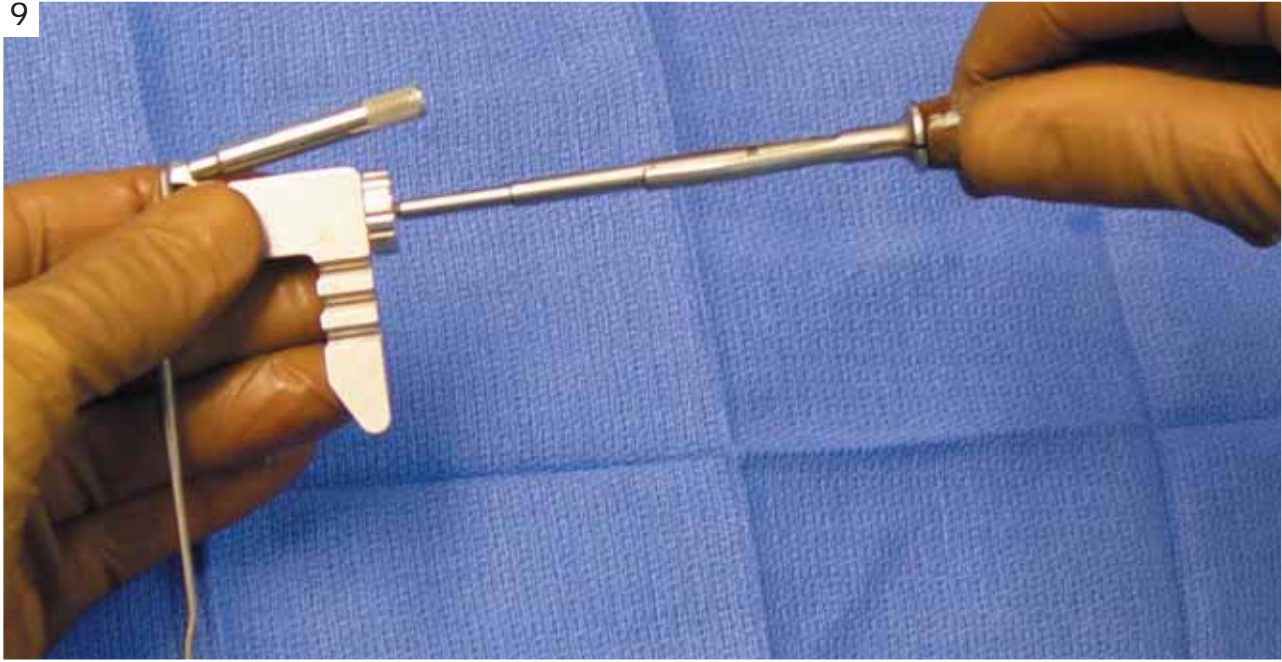
Create a notch on the proximal fragment in line with the floor of the 3rd compartment to receive the neck of the implant.

8



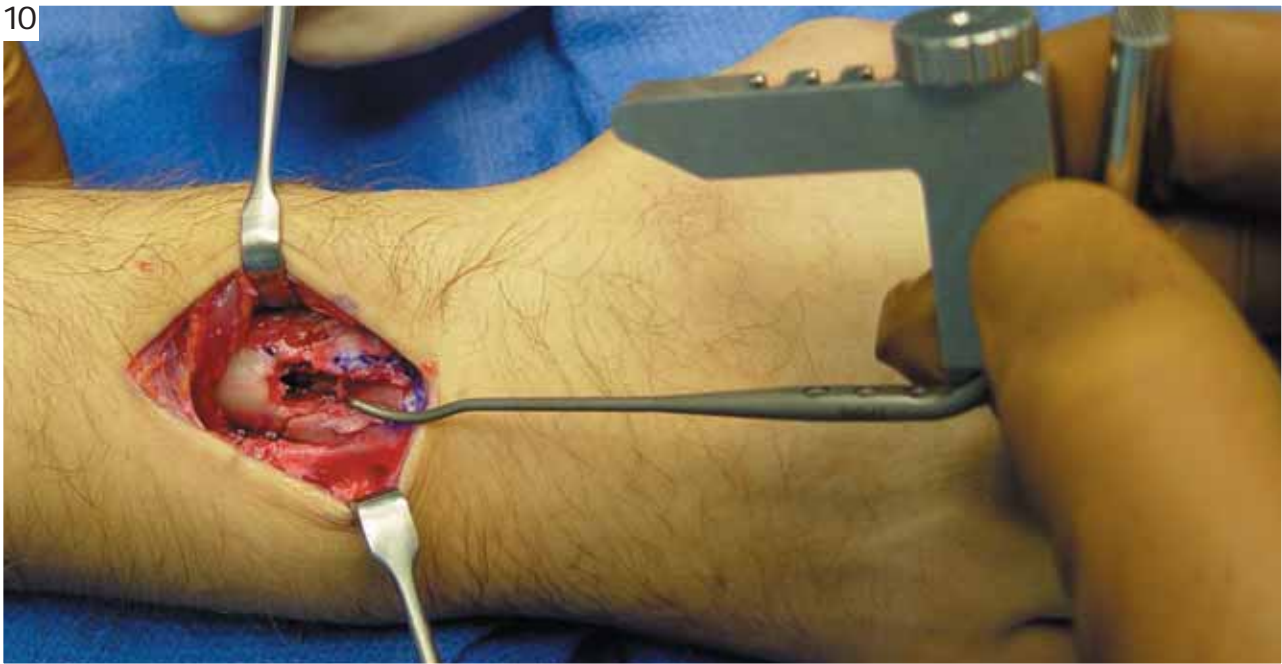Open the medullary canal.

9



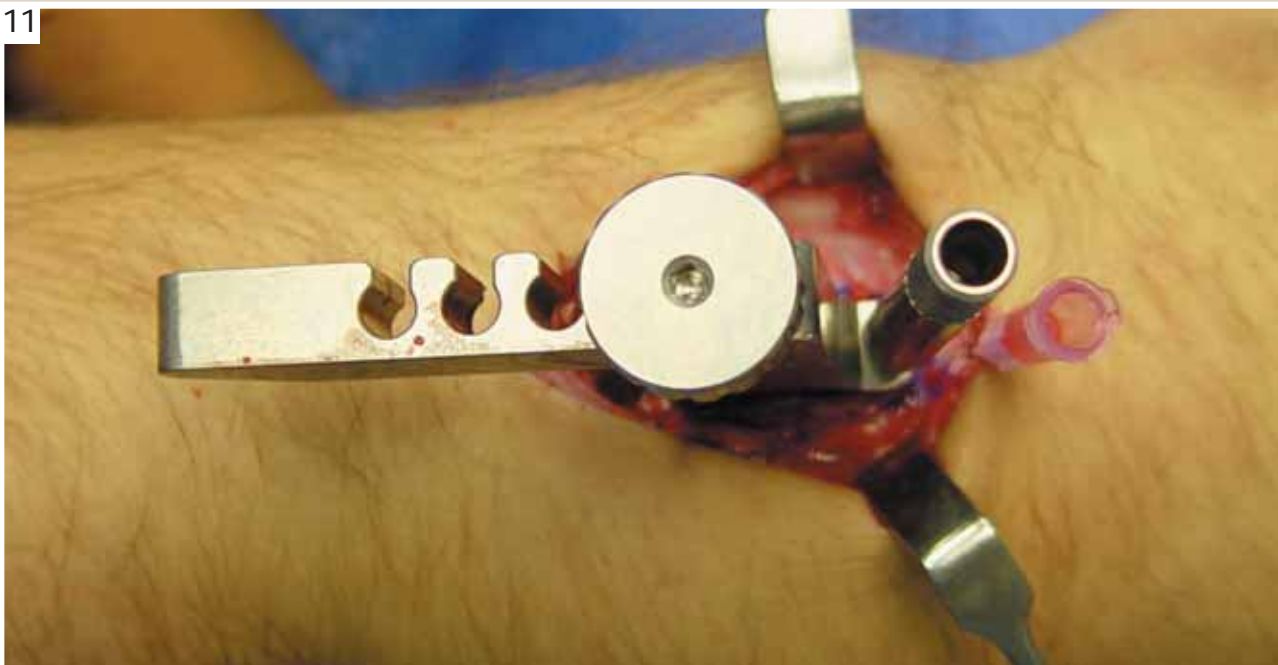
Attach the insertion jig to the implant and apply the threaded drill guide to the most distal peg hole.

10



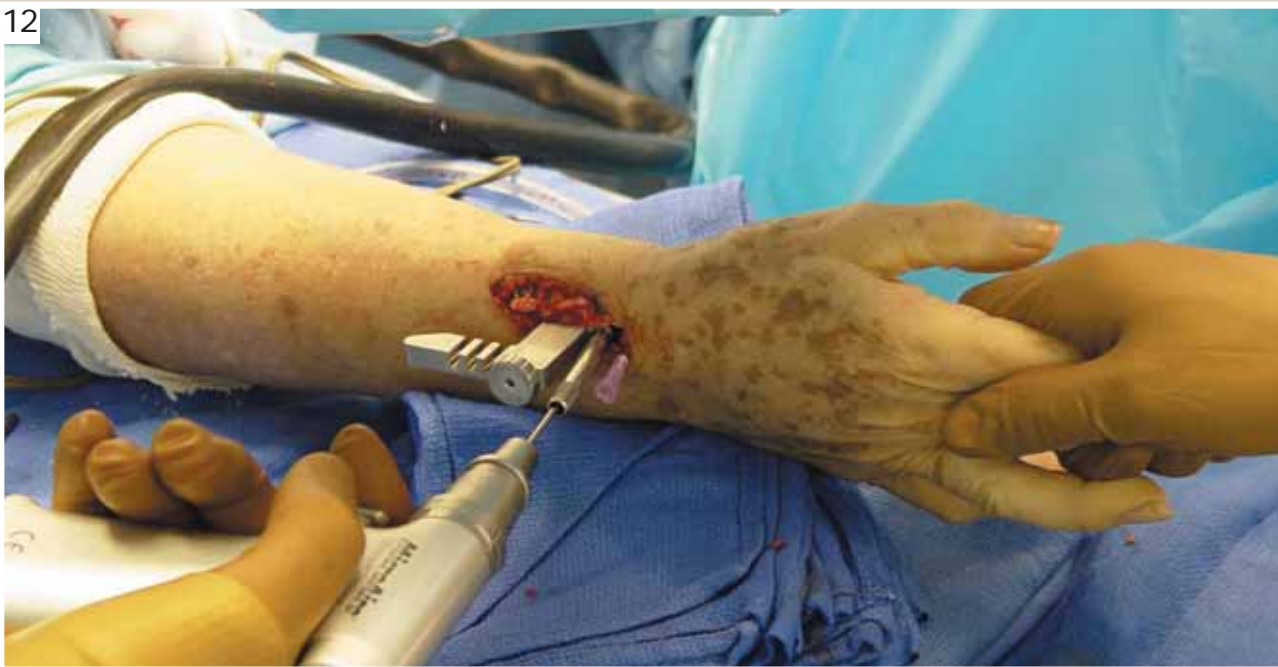Insert the nail plate into the medullary canal and advance it with a gentle rotational motion.

11



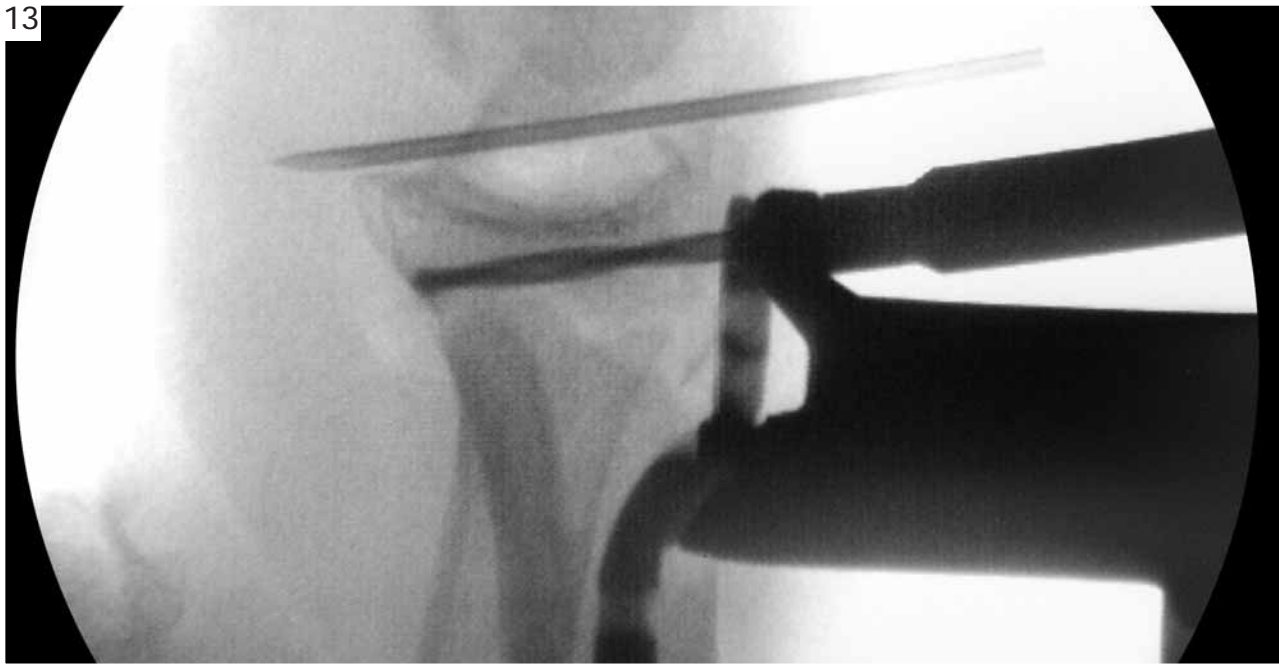
Seat the head of the implant flush on the distal fragment;
then assure its correct rotation.

12



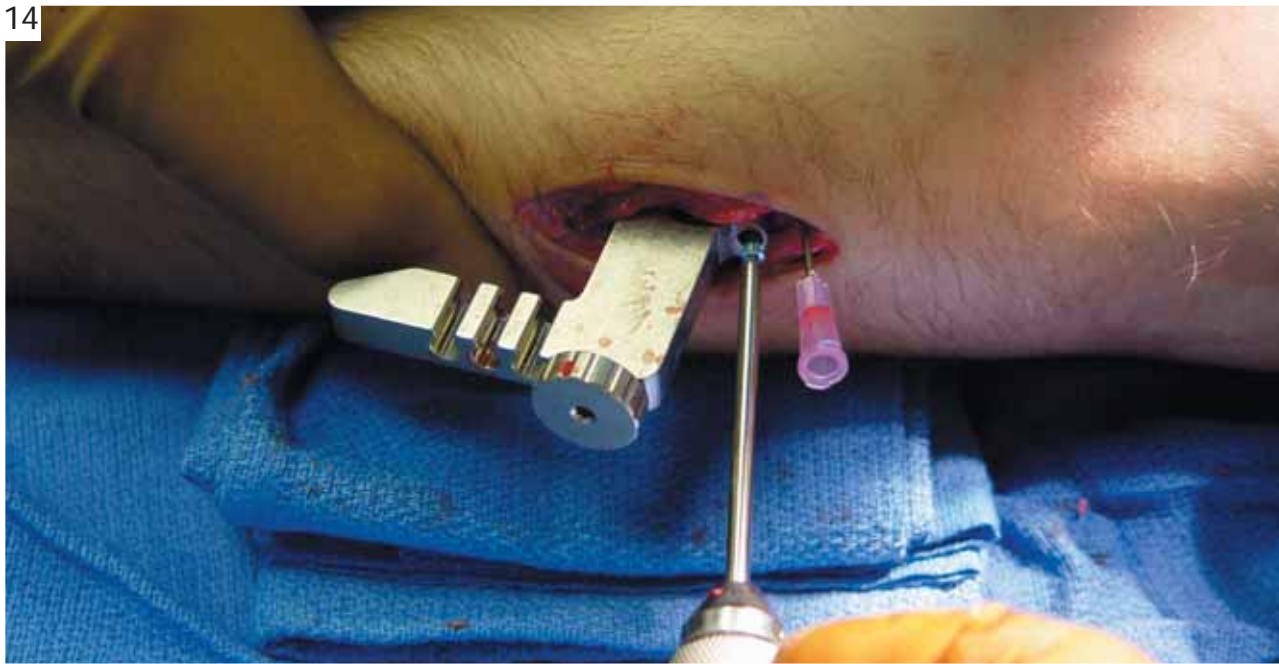
Under fluoroscopic guidance and while maintaining reduction, insert a 2mm bit
through the threaded drill guide to create the tract for the central peg.

13



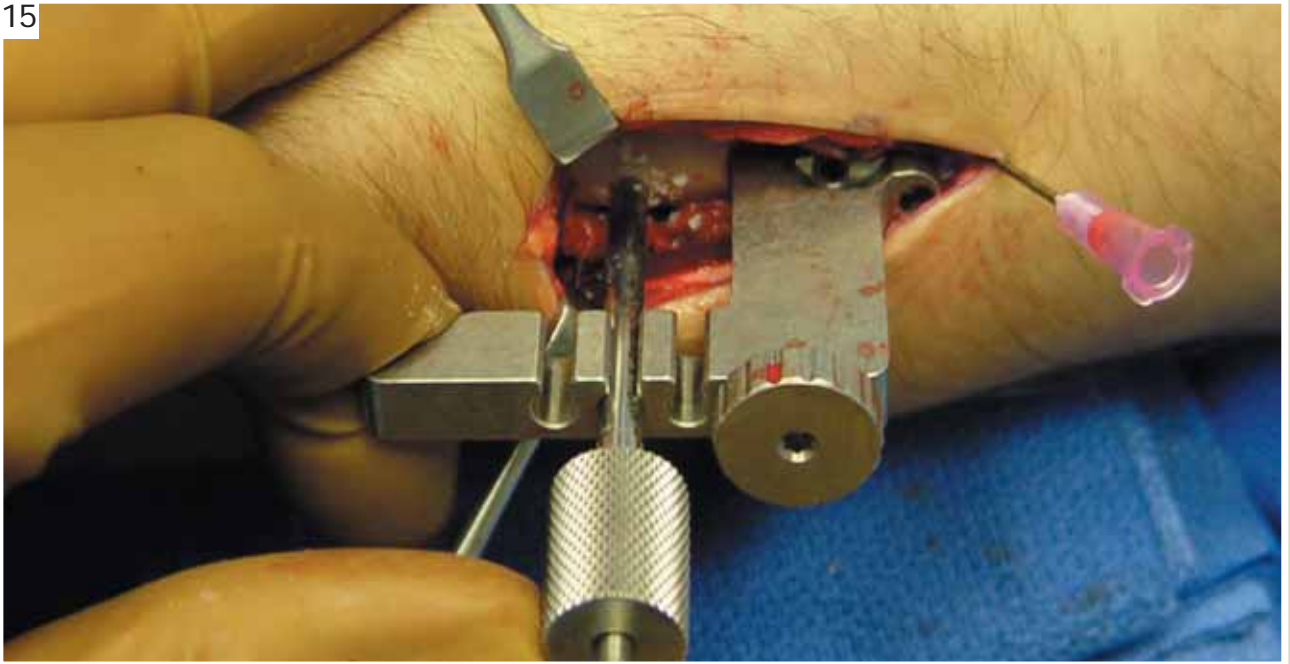
The drill should course immediately below the subchondral bone; this is best visualized in a 30 deg. lateral elevation view.

14



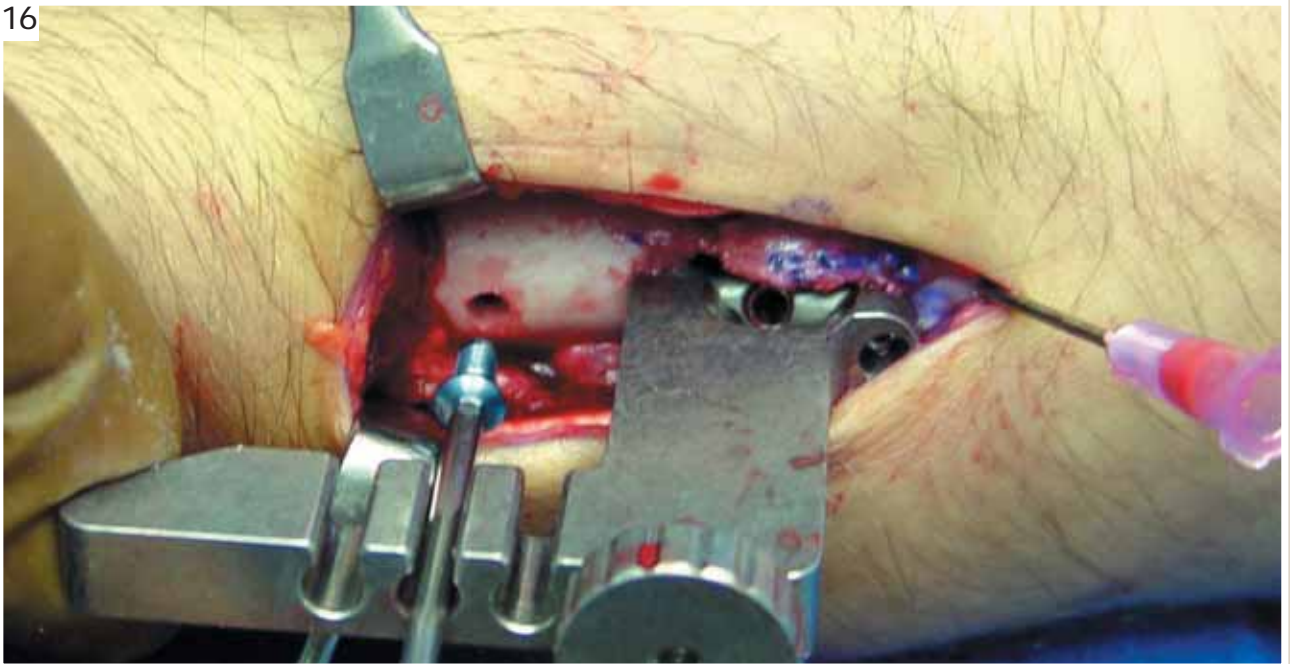
Apply the central peg after carefully measuring its length. Use a smooth peg and avoid protrusion through the volar cortex as this may cause soft tissue problems.

15



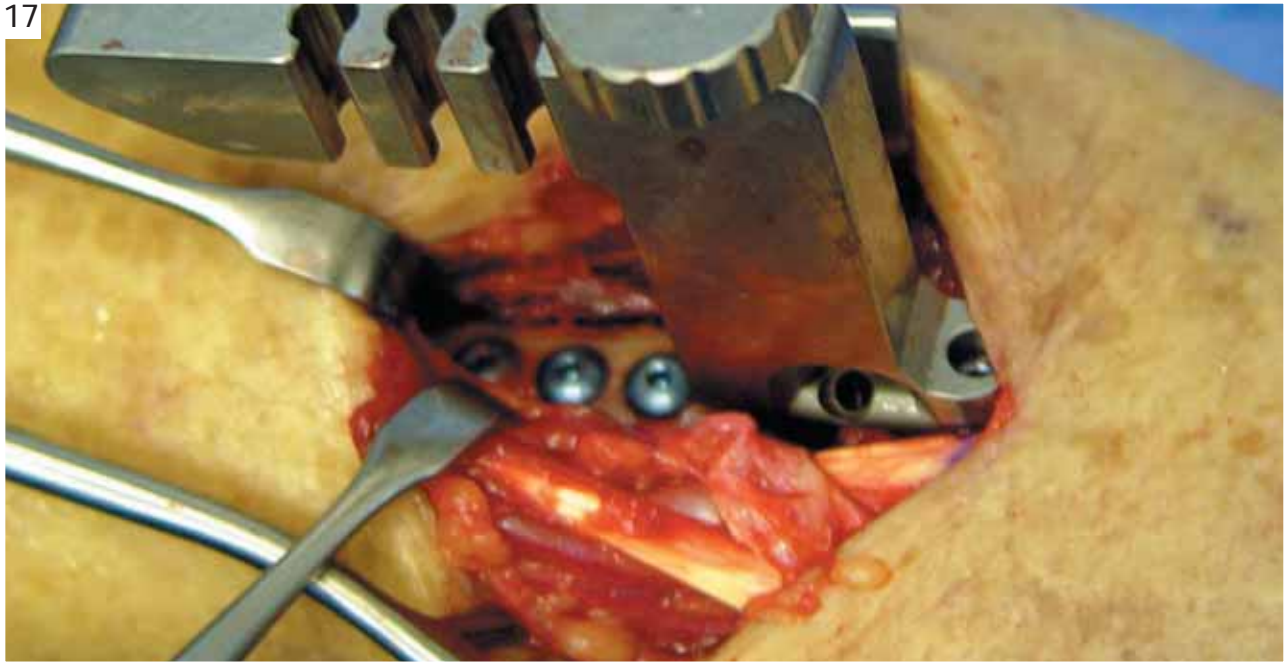
Apply the proximal cortical locking screws next. Insert the drill sleeve into a slot on the jig and push it down to the bone surface. Drill a unicortical hole with the 3.3 mm bit.

16



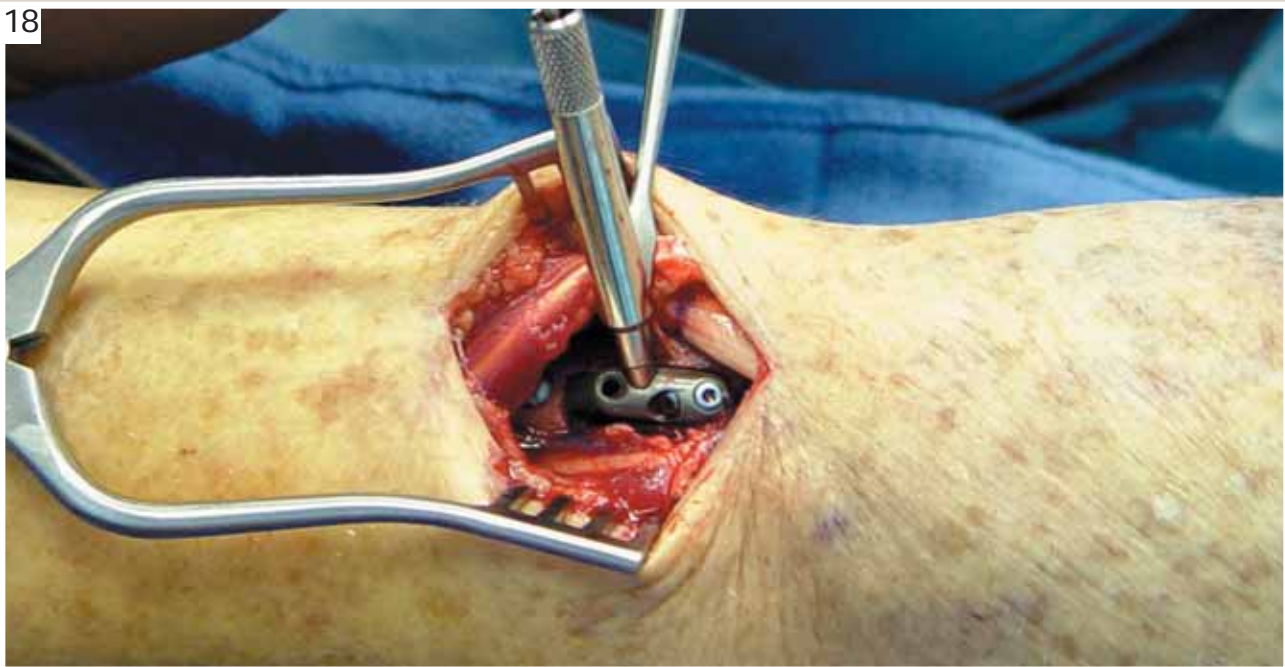
Remove the drill sleeve and apply the cortical locking screw with the square ended driver.

17



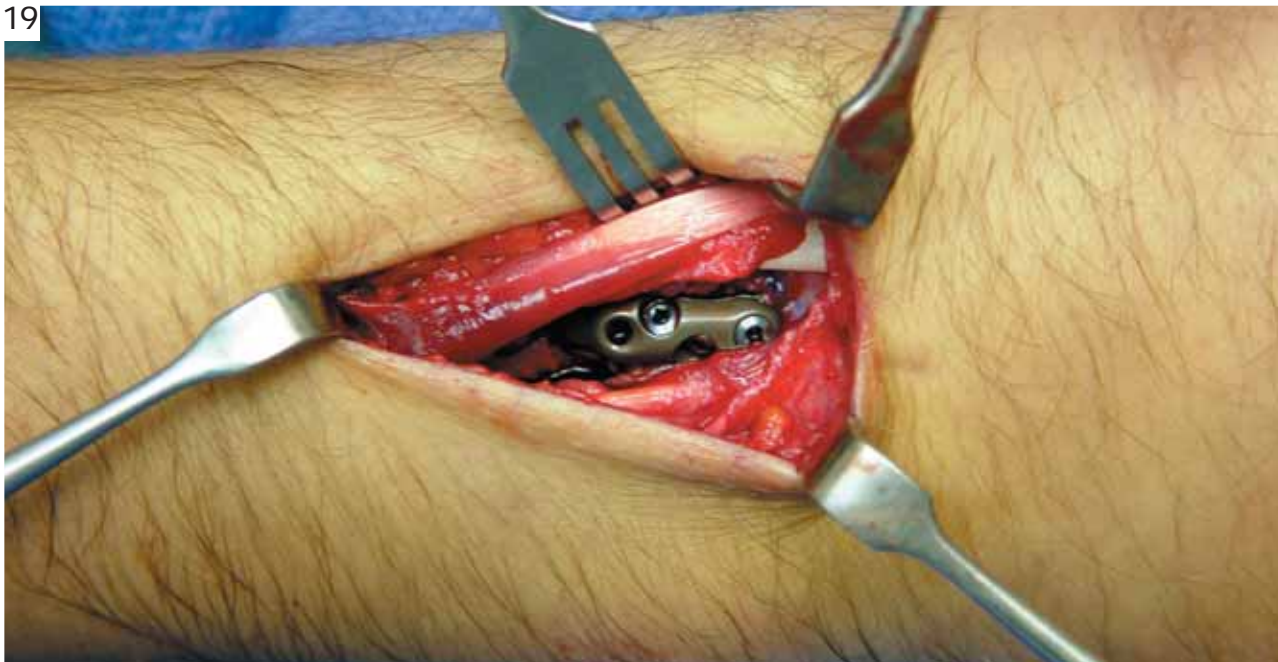
Repeat these steps for each proximal screw; re-tighten previous screws.

18



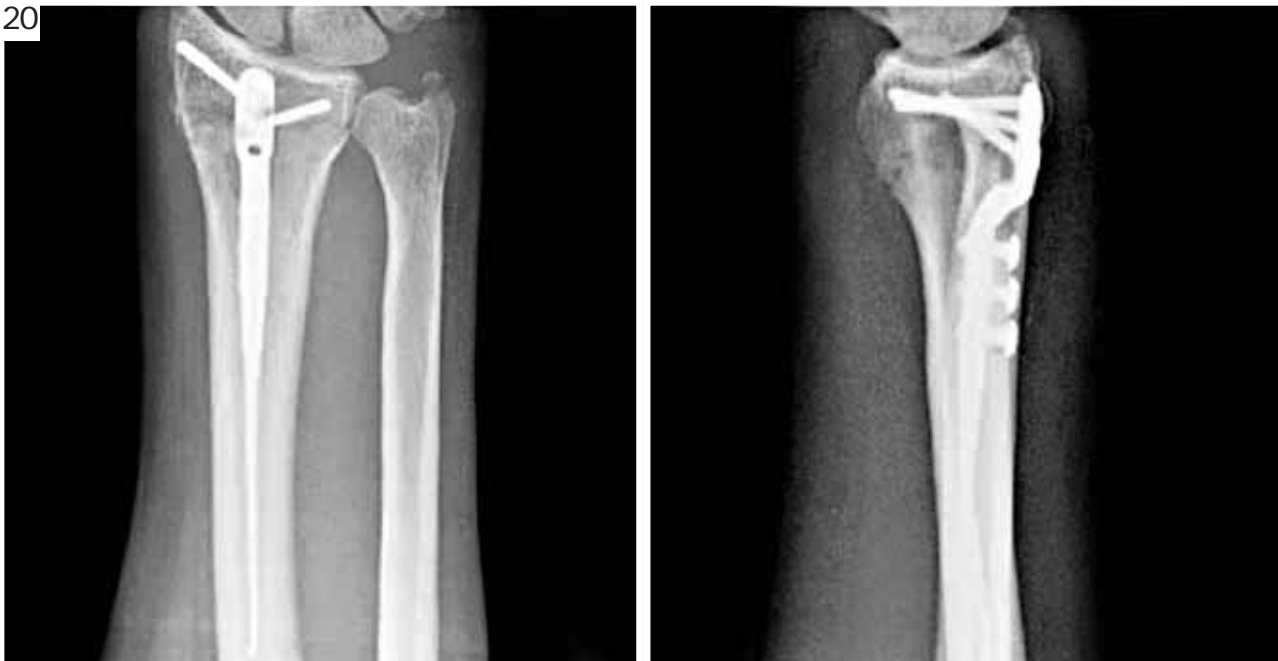Remove the insertion jig and use the threaded drill guide to apply the two remaining distal pegs. While drilling, push the distal fragment up and against the implant. This will assure the head is flush with its surface. Do not protrude through the opposite cortex.

19



After proper application of the DNP, the EPL tendon should course proximal to the head of the implant and the tendons of the 2nd and 4th compartments on each side of it. There should be no impingement.

20



Obtain final radiographic views, close the wound with proper surgical technique, apply a post-operative dressing and encourage immediate finger motion. The use of removable splint for three to four weeks is advisable.

for more information contact:



8905 sw 87th avenue, suite 220
miami, florida 33176
telephone: 305.412.8010
fax: 305.412.8060
toll free no.: 800.800.8188
www.handinnovations.com